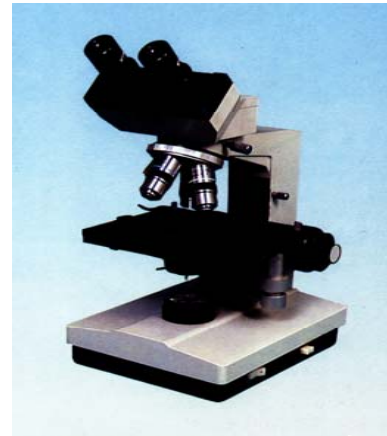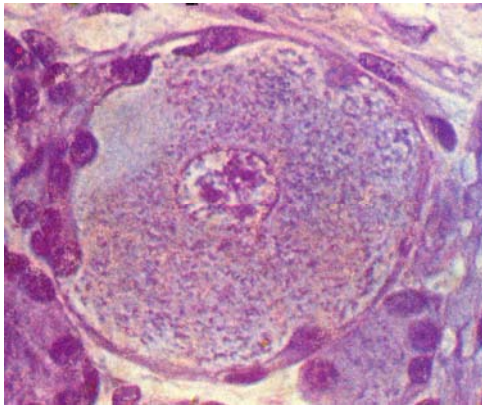



Histology and Embryology



- Chapter 1 Introduction and Cell**
- Chapter 2 Epithelial tissue**
- Chapter 3 Connective Tissue**
- [Chapter 4 Blood](#)**
- Chapter 5 Cartilage and Bone**
- Chapter 6 Muscle Tissue**
- Chapter 7 Nerve Tissue**
- Chapter 8 Circulatory System**
- Chapter 9 Immune System**
- Chapter 10 Skin**
- Chapter 11 Digestive Tract**
- Chapter 12 Digestive Gland**
- Chapter 13 Respiratory System**
- Chapter 14 Urinary System**
- Chapter 15 Endocrine System**
- Chapter 16 Sense Organ**
- Chapter 17 Male Reproduction**
- Chapter 18 Female Reproduction**
- Chapter 19 Embryology 1**
- Chapter 20 Embryology 2**

Chapter 4 Blood

I Slides

II Section

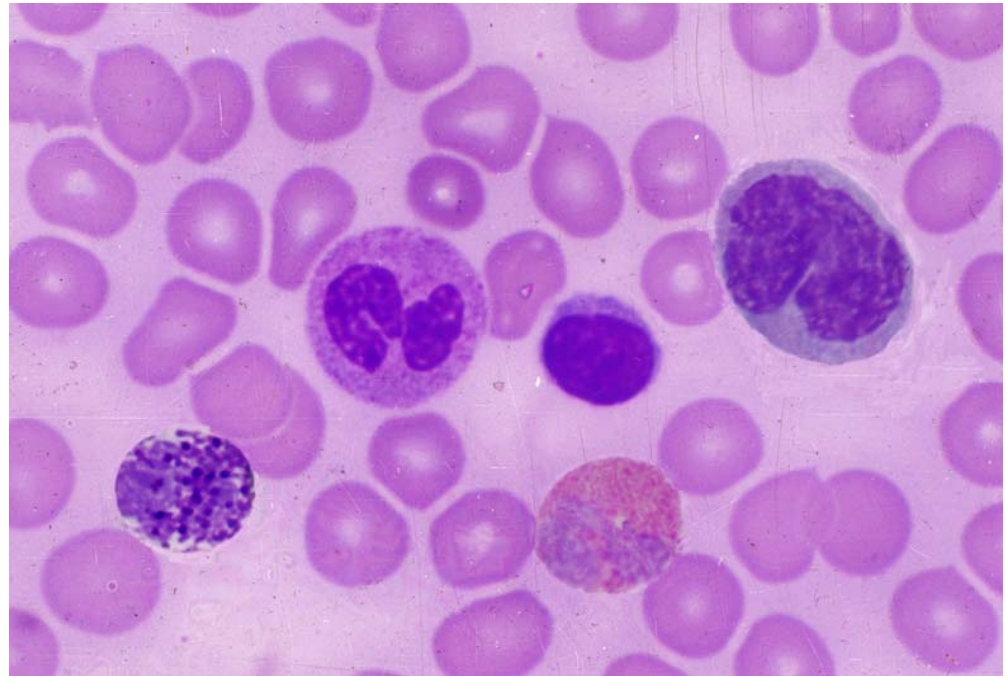
No.9 Blood smear

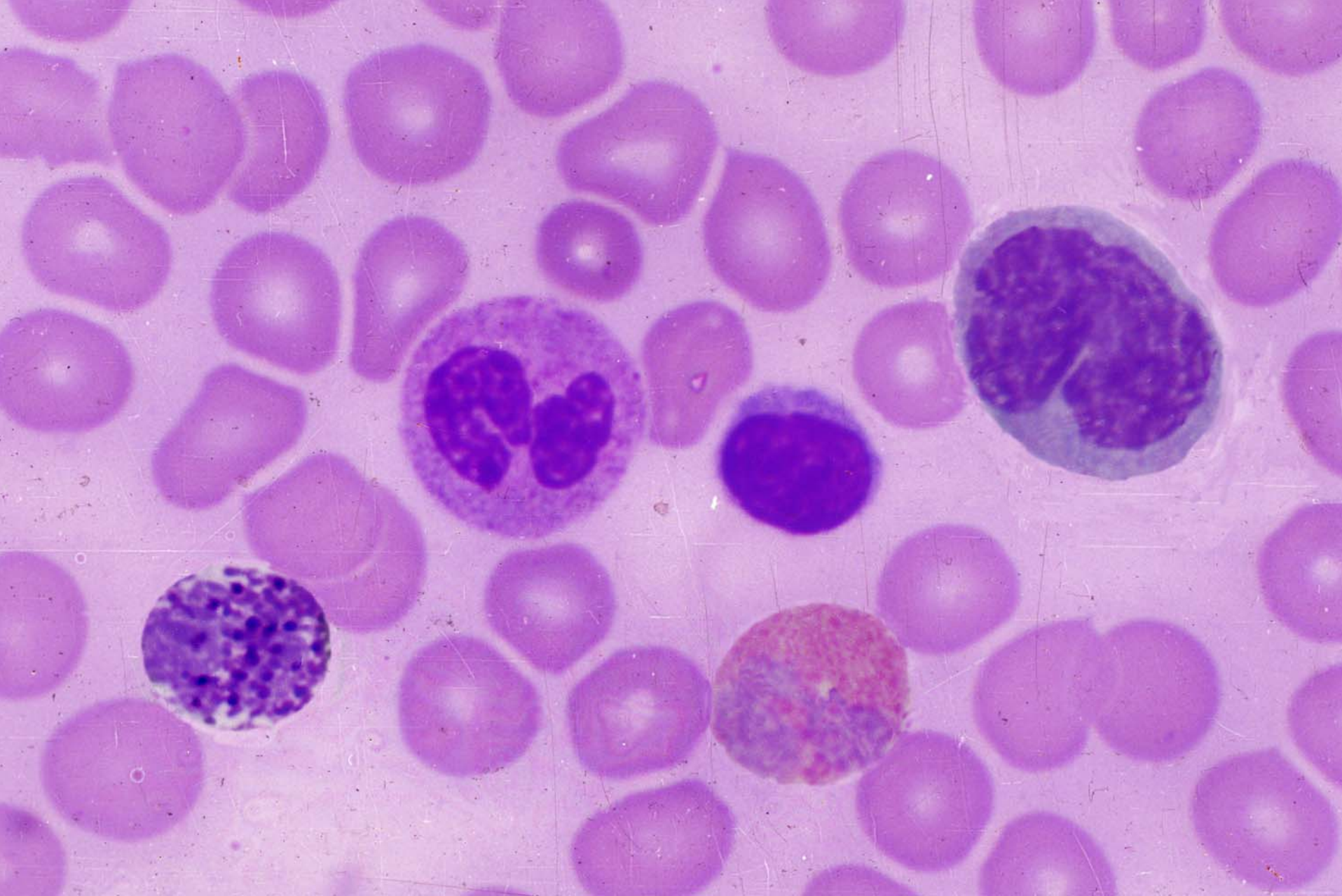
III Do blood smear

IV EM photos: 17-20

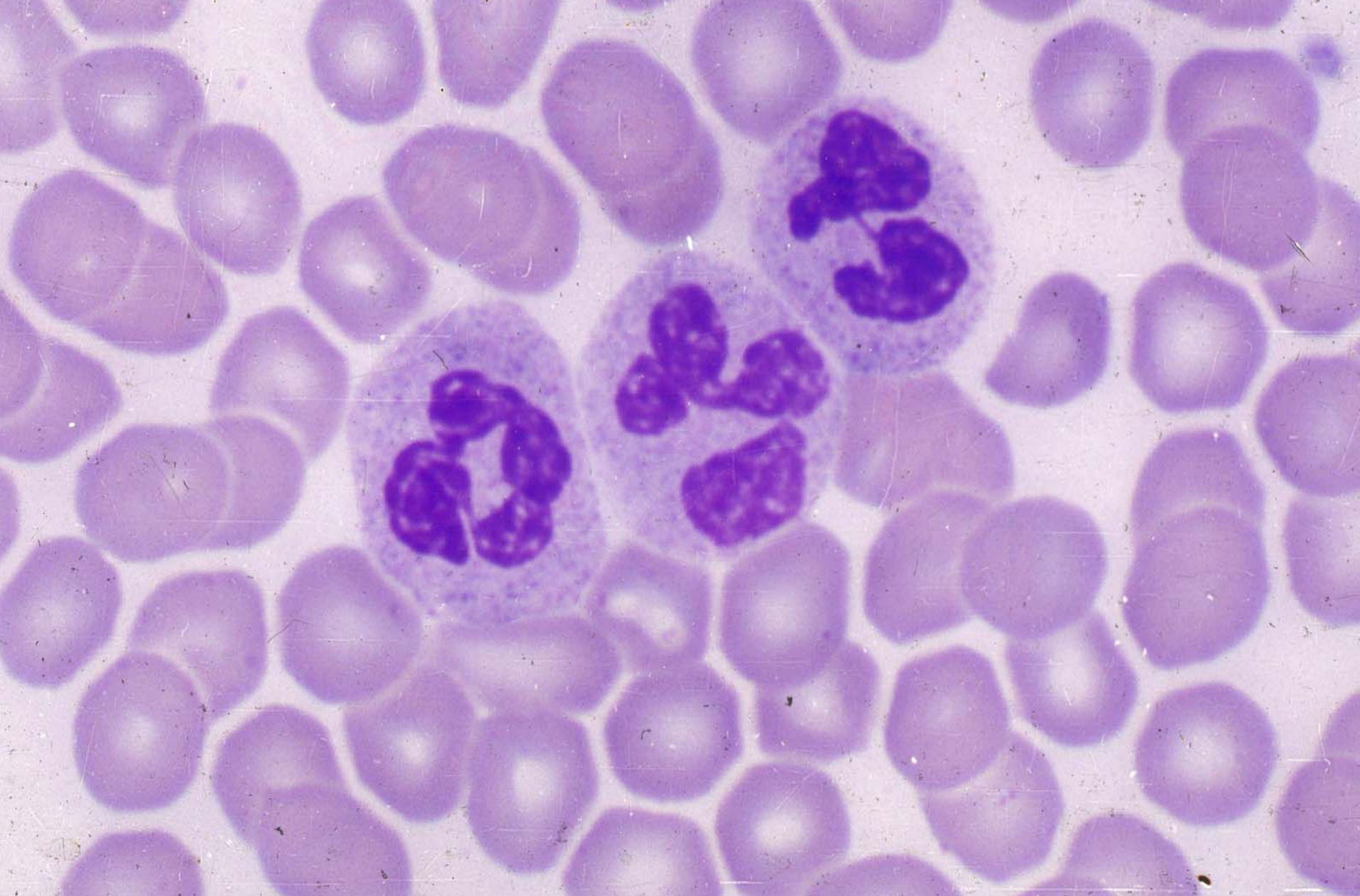
V Drawing: Blood cells

VI Demonstration: Basophila

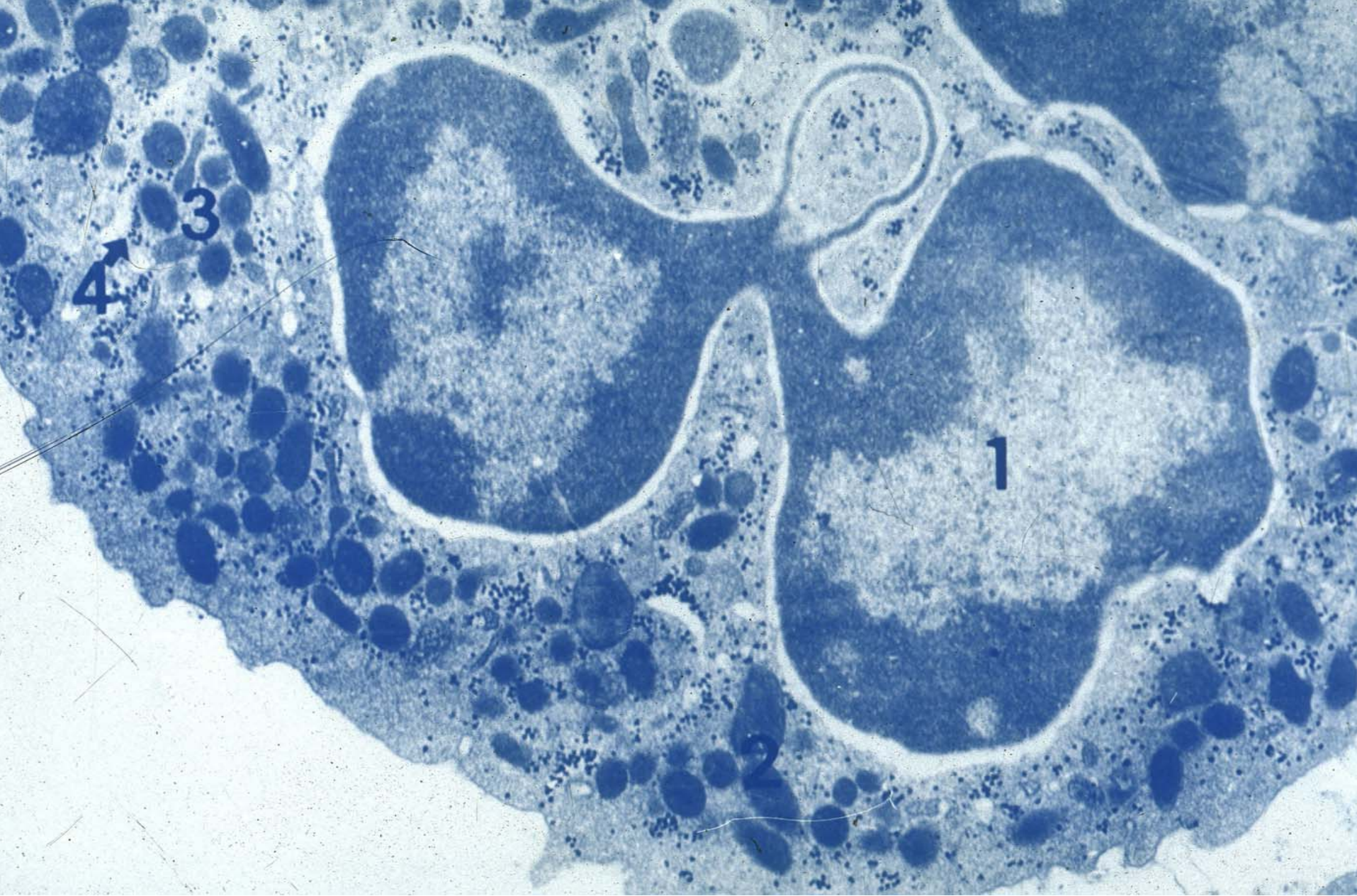




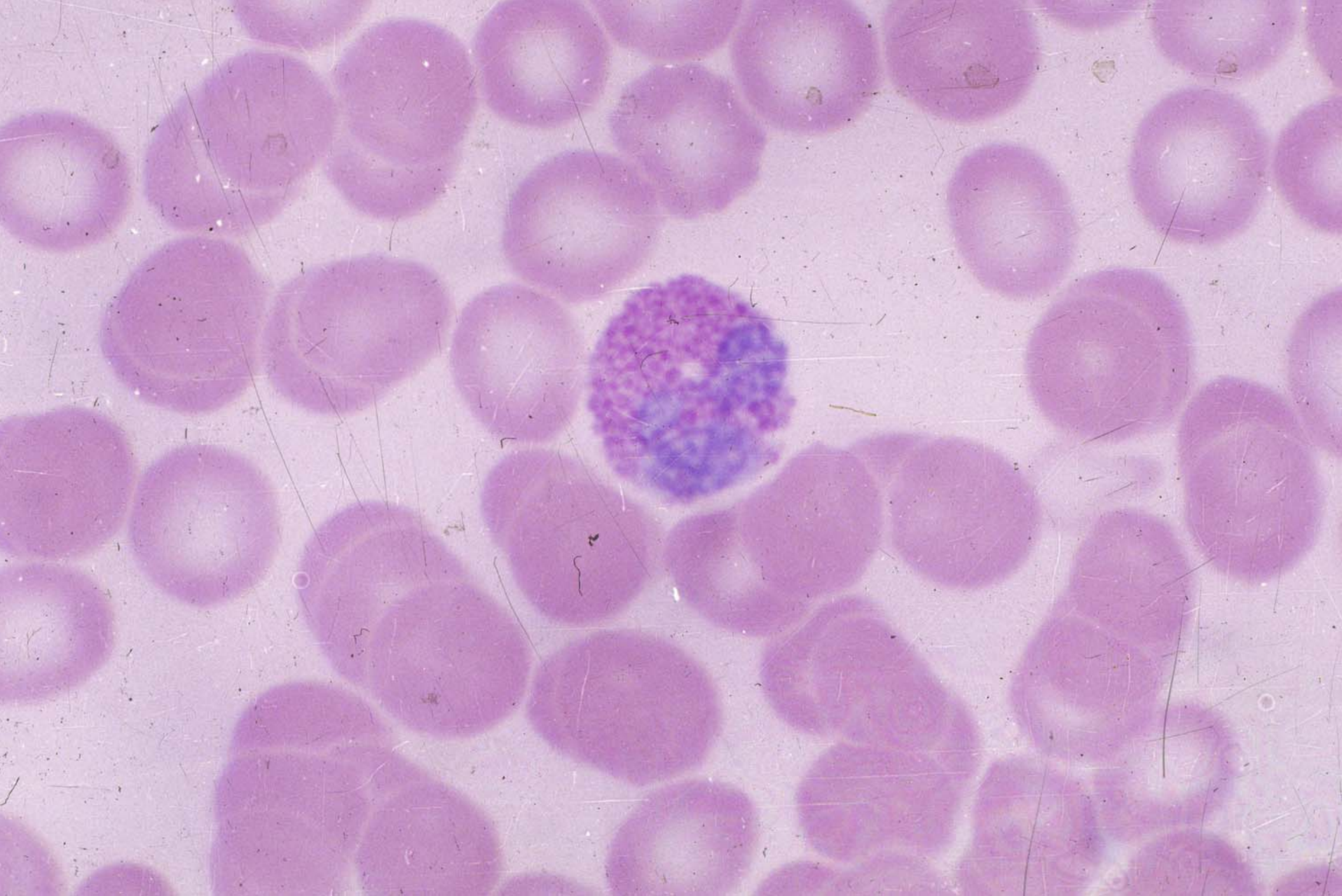
Erythrocyte and leukocyte



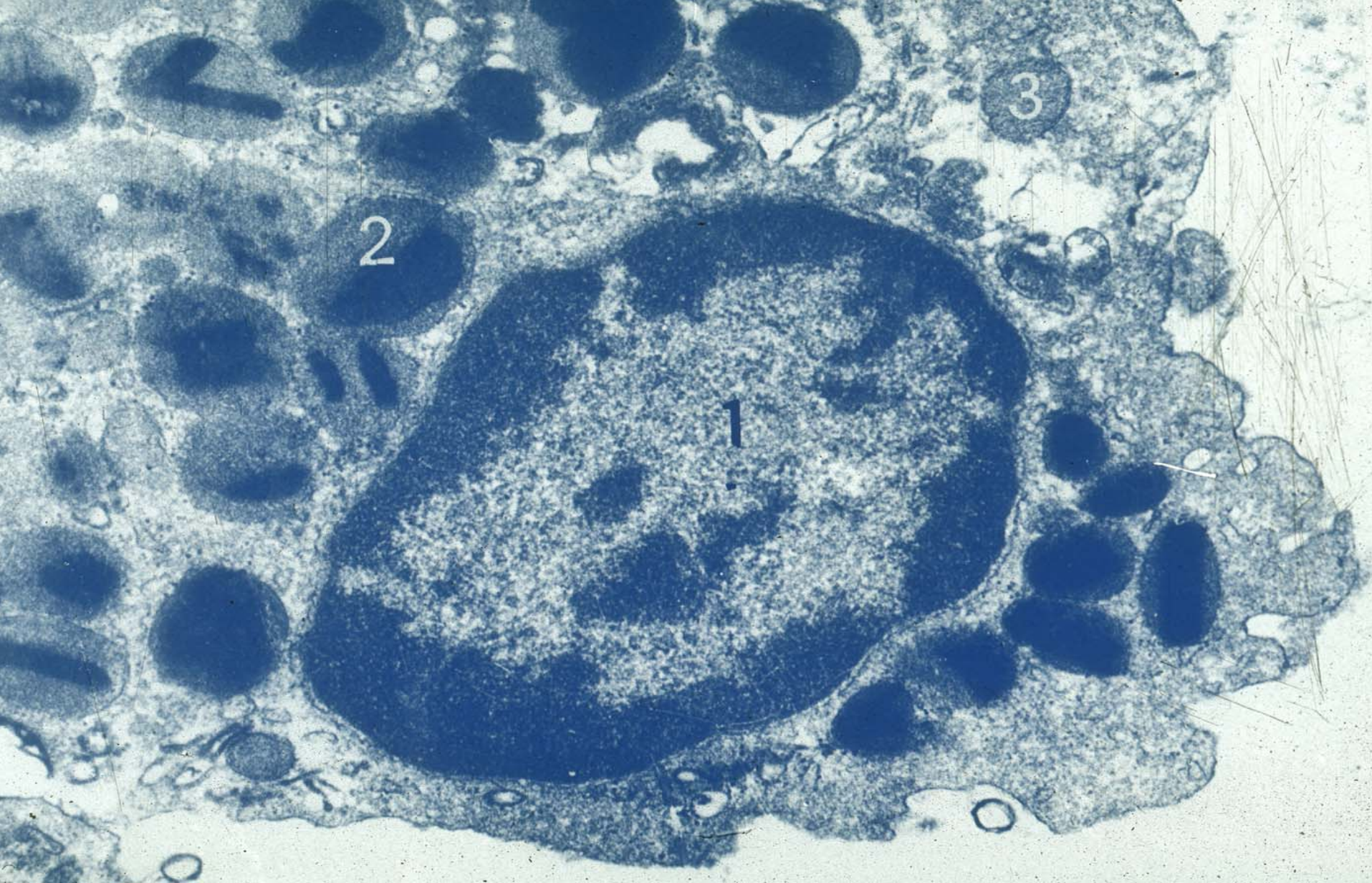
Erythrocyte and Neutrophil



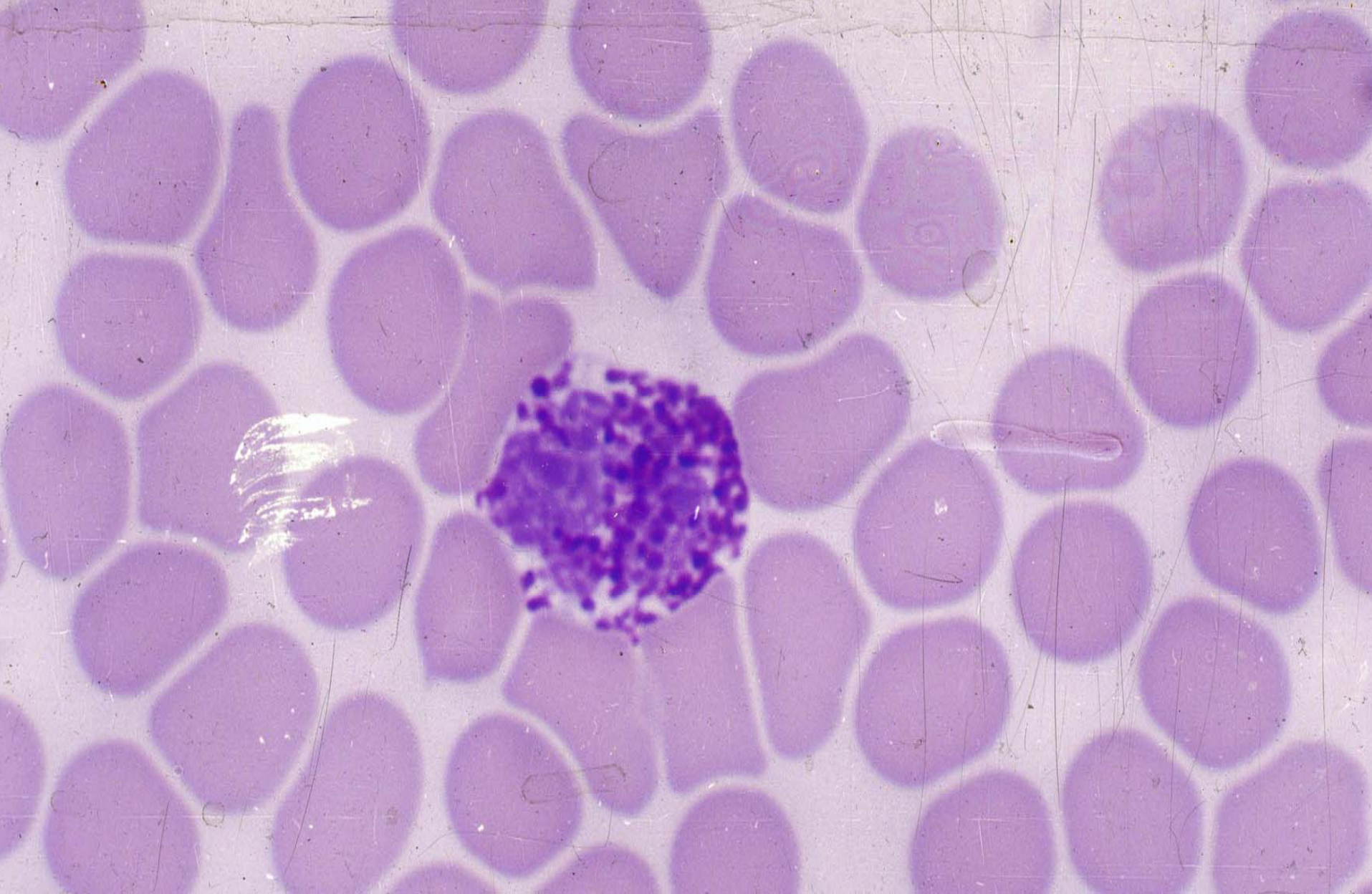
Neutrophil



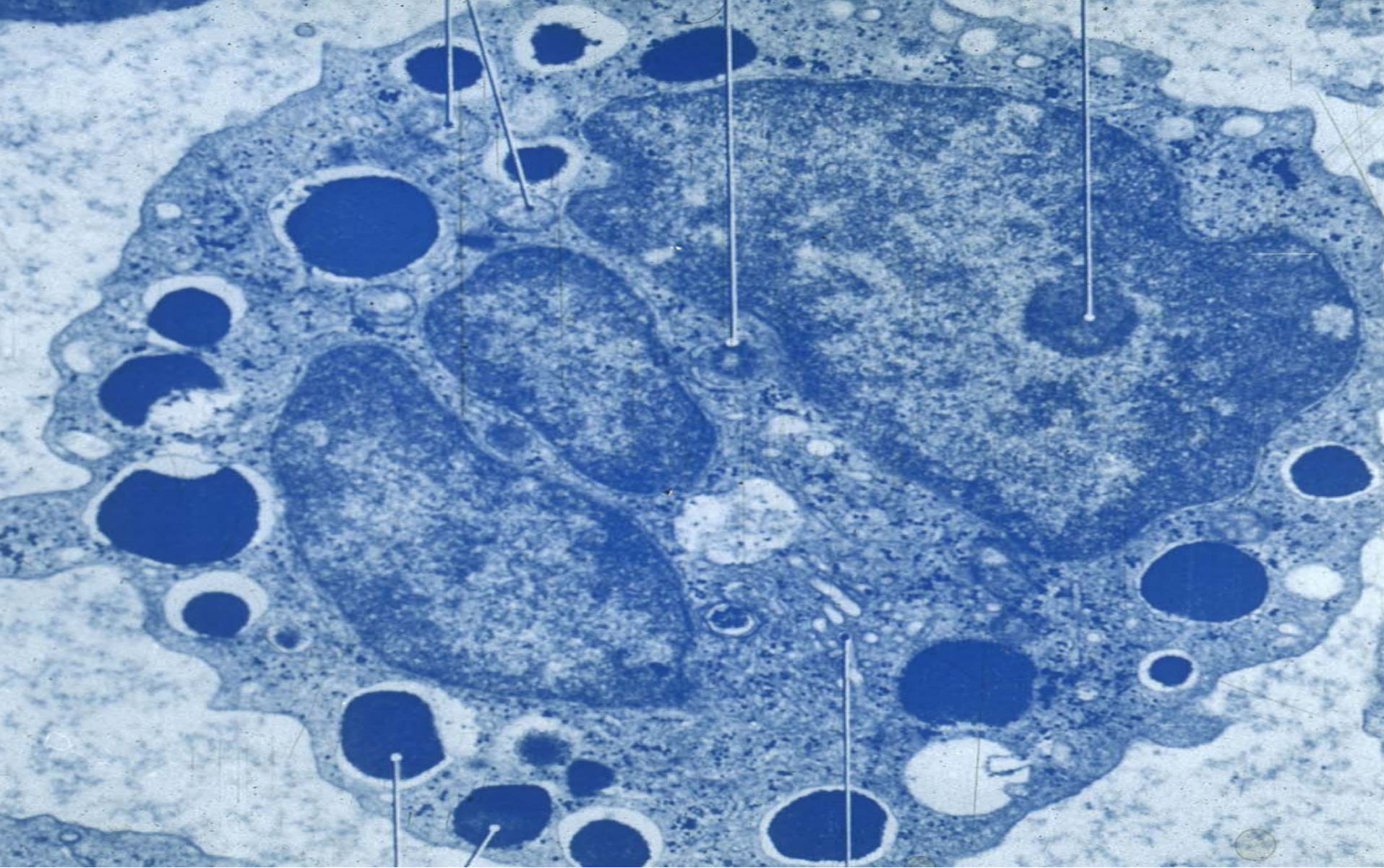
Erythrocyte and Eosinophil



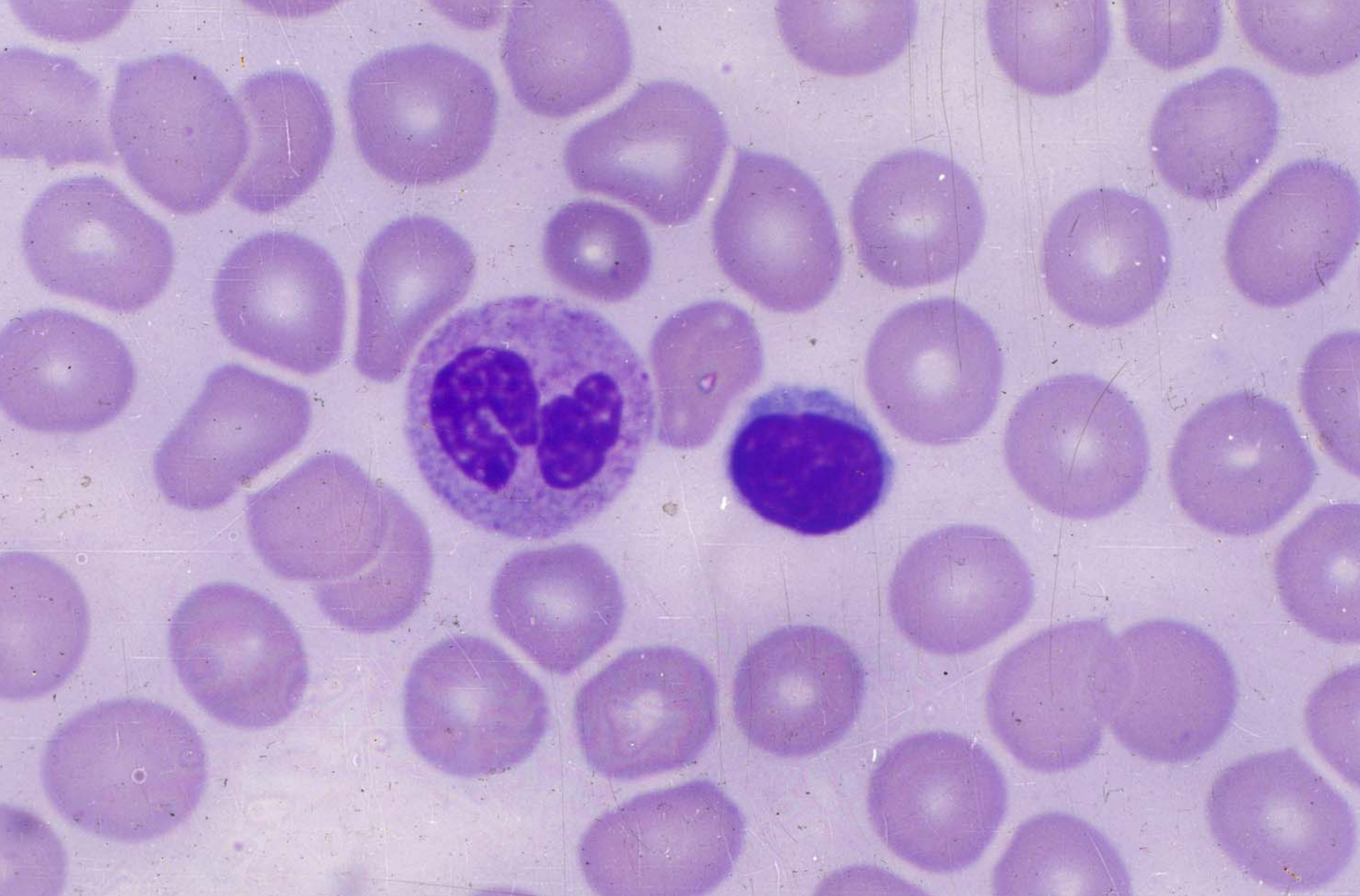
Eosinophil



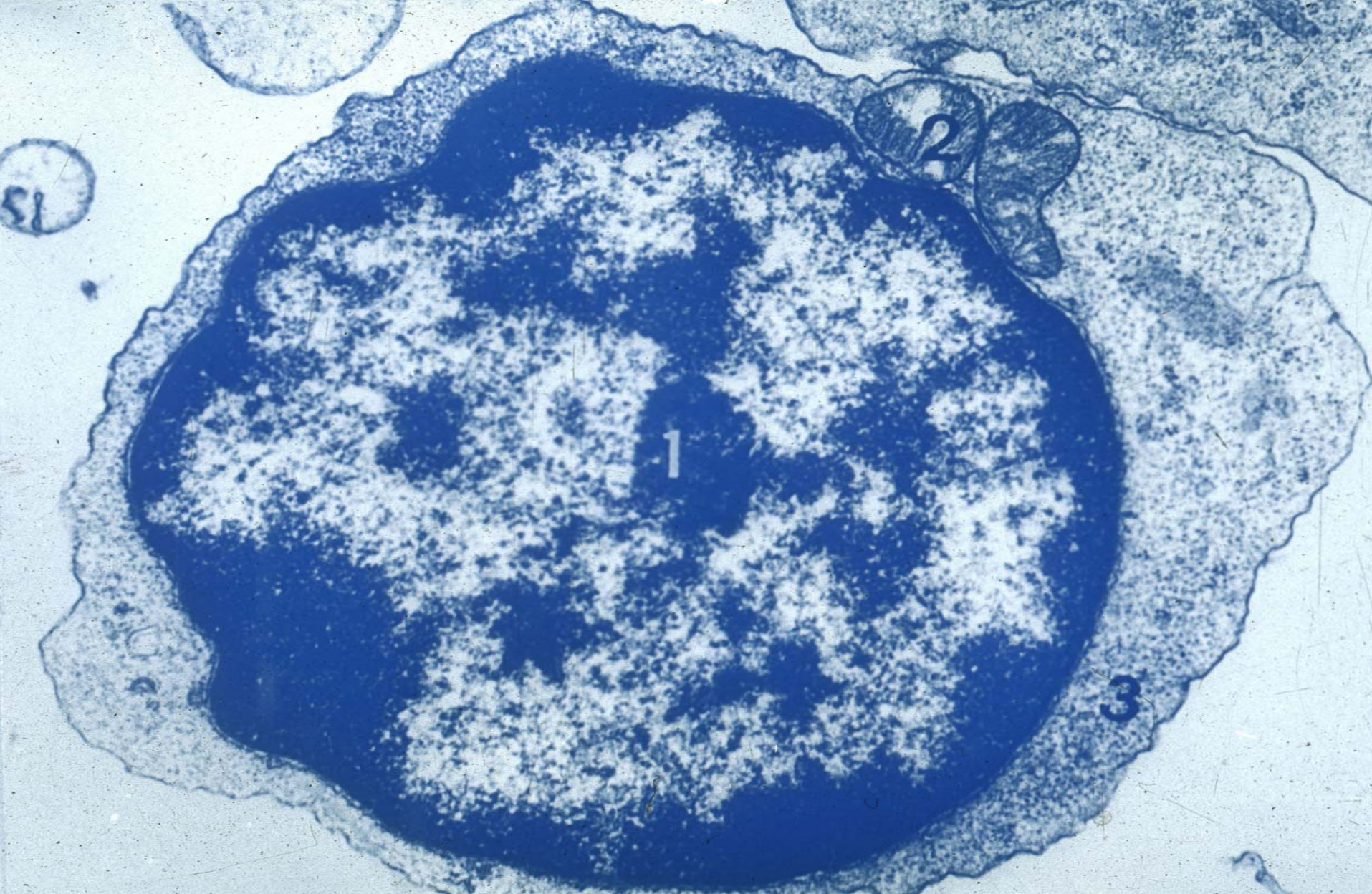
Erythrocyte and Basophil



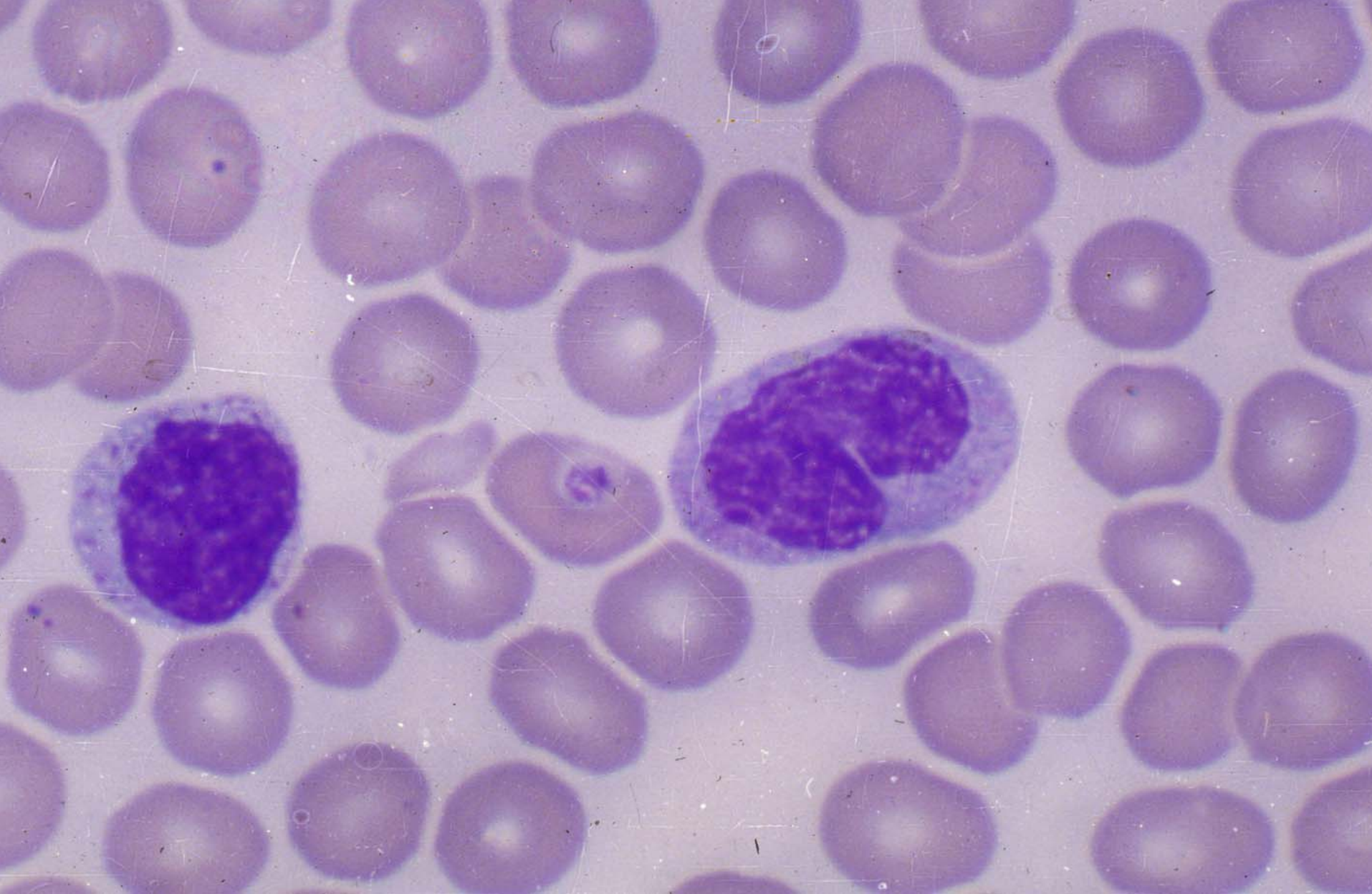Basophil



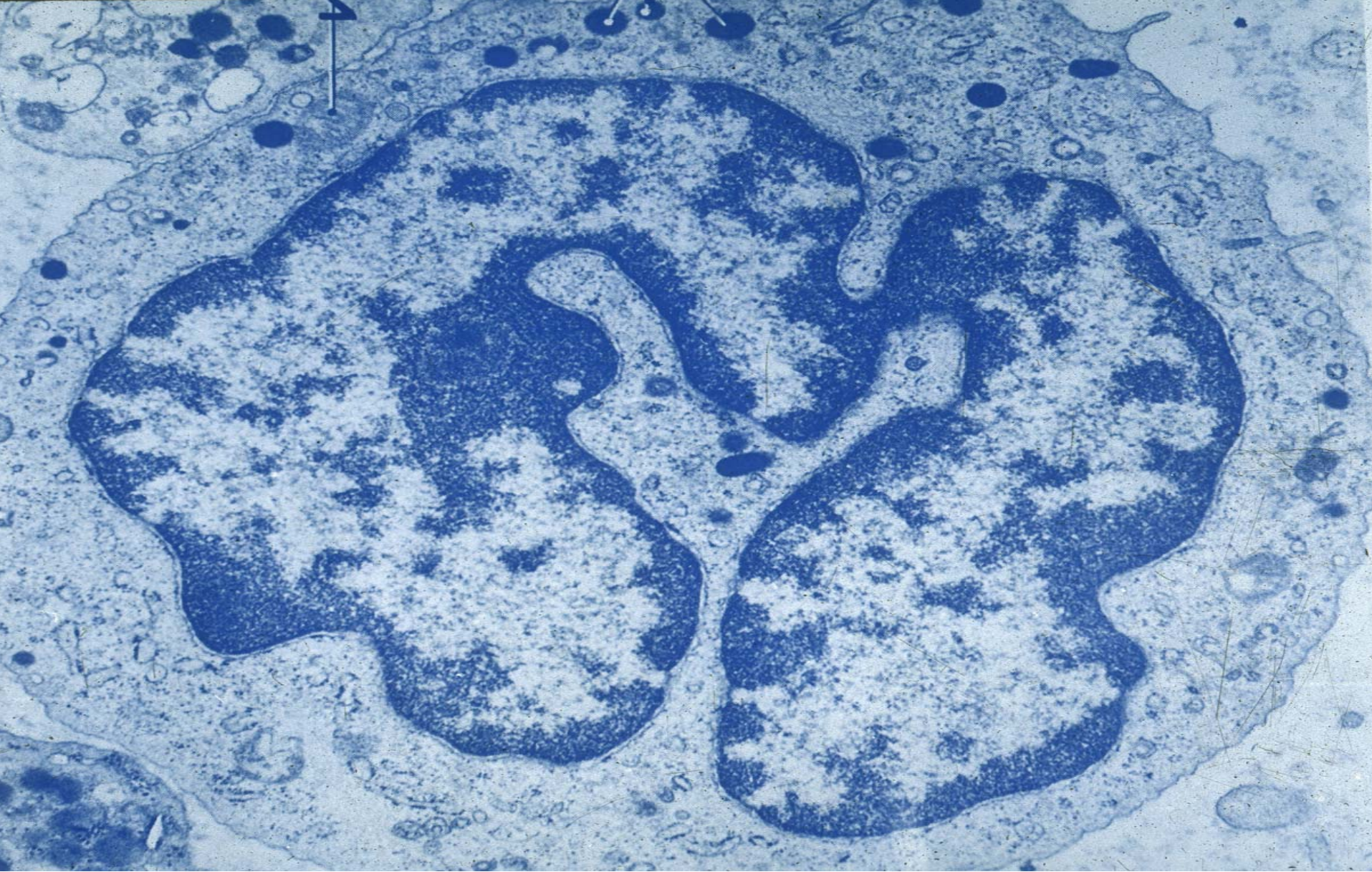
Erythrocyte , Neutrophil and Lymphocyte



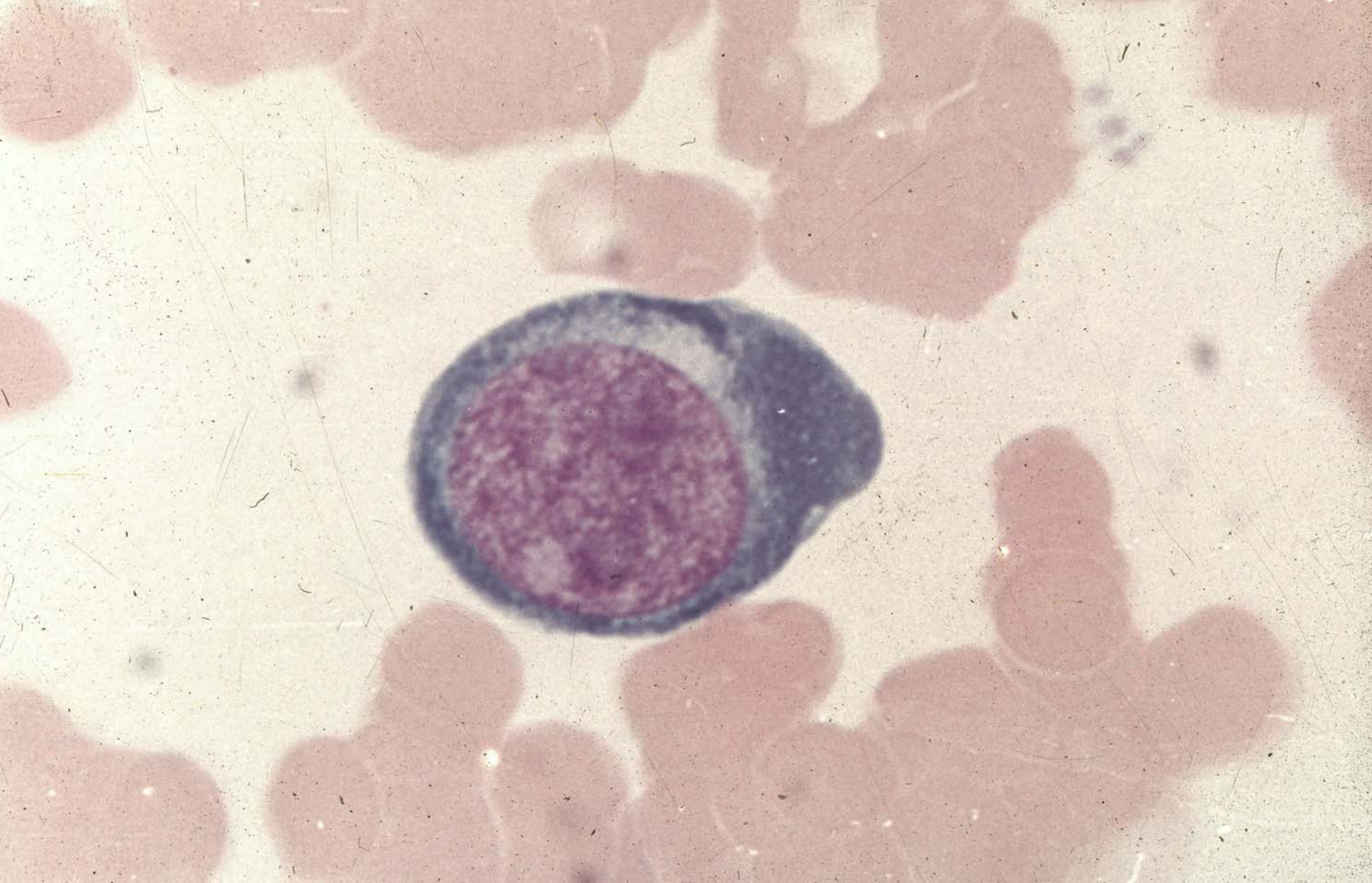
Lymphocyte



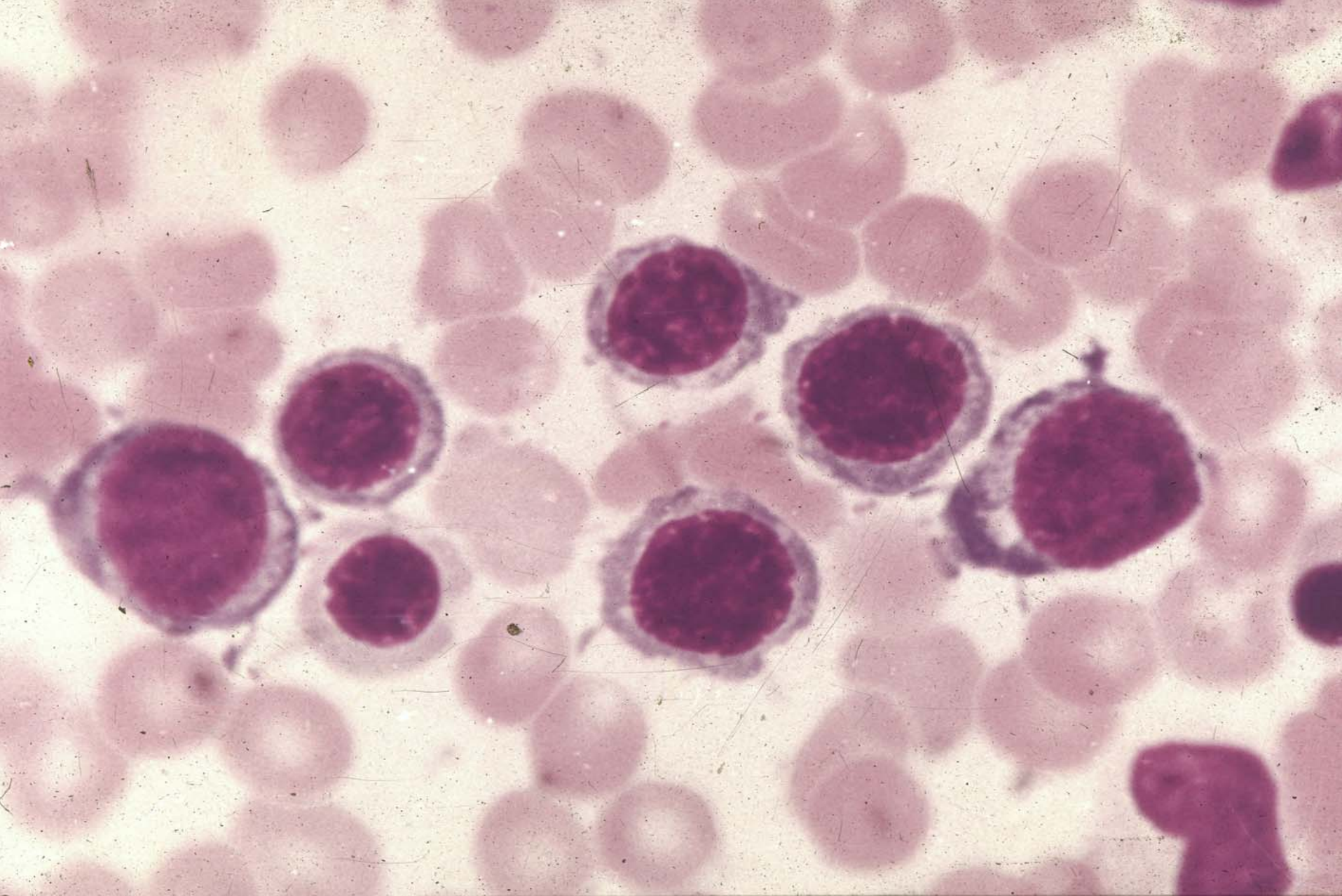
Blood Platelet , Erythrocyte , Lymphocyte and Monocyte



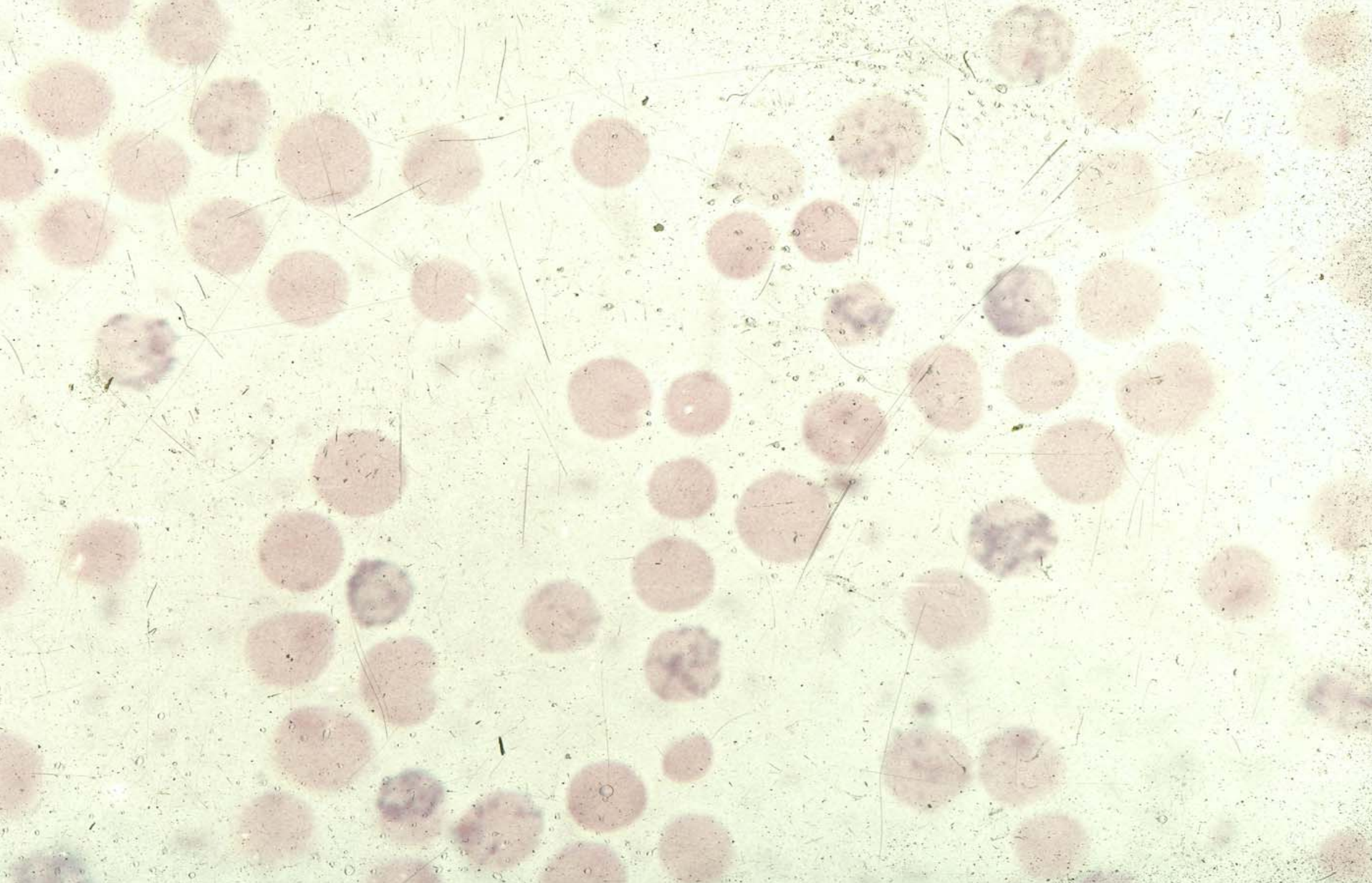
Monocyte



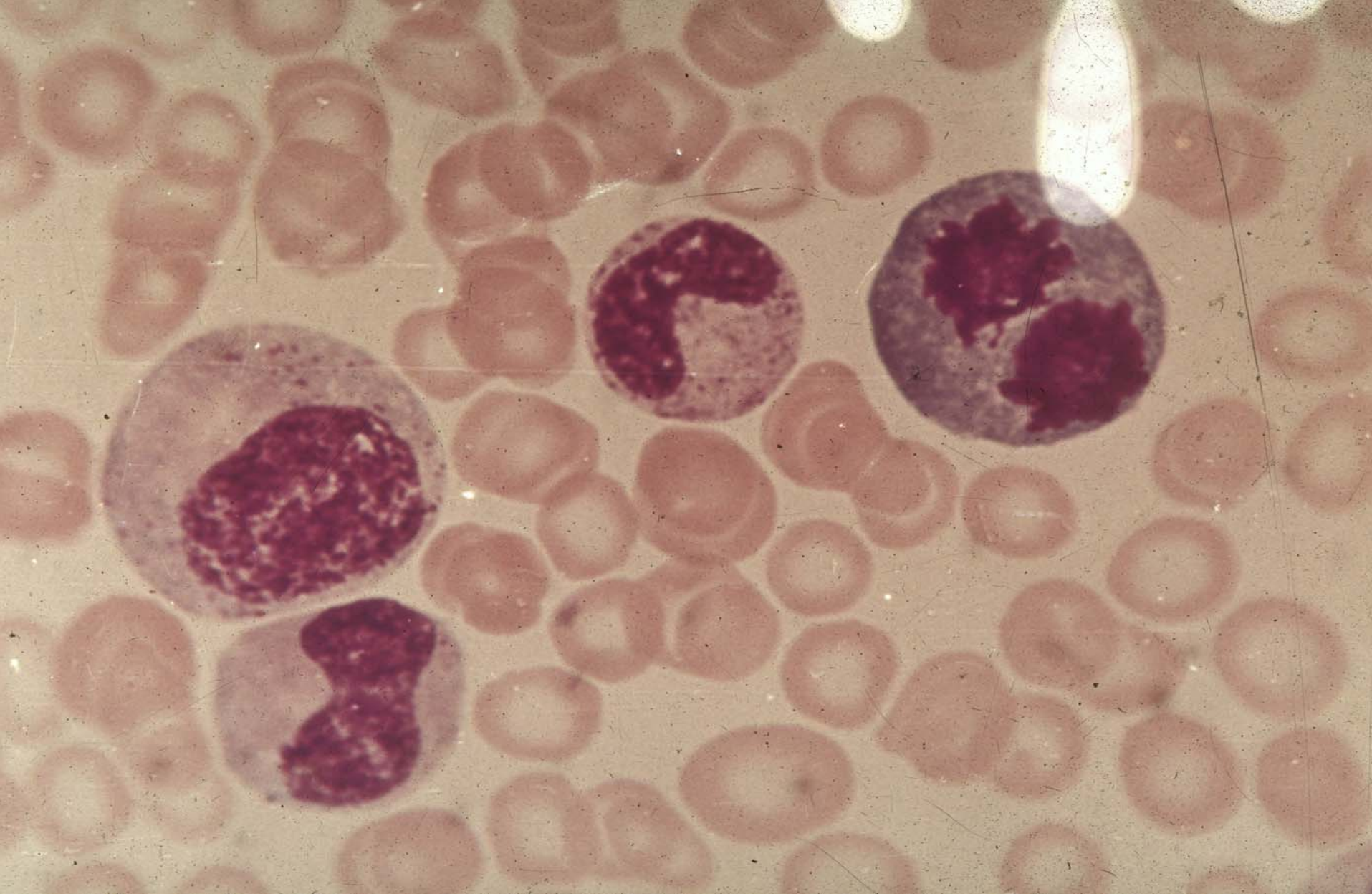Proerythroblast



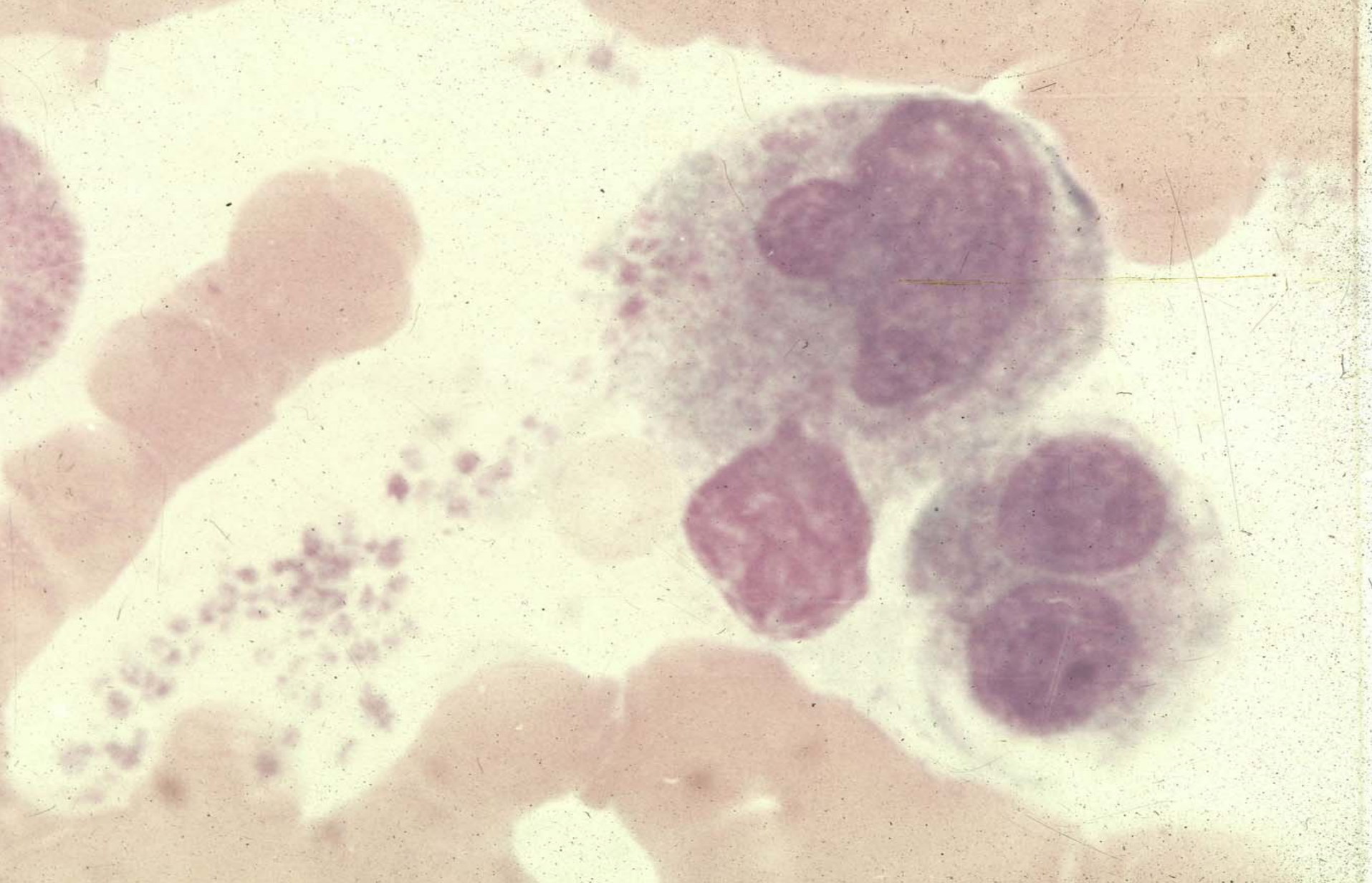
Erythroblast



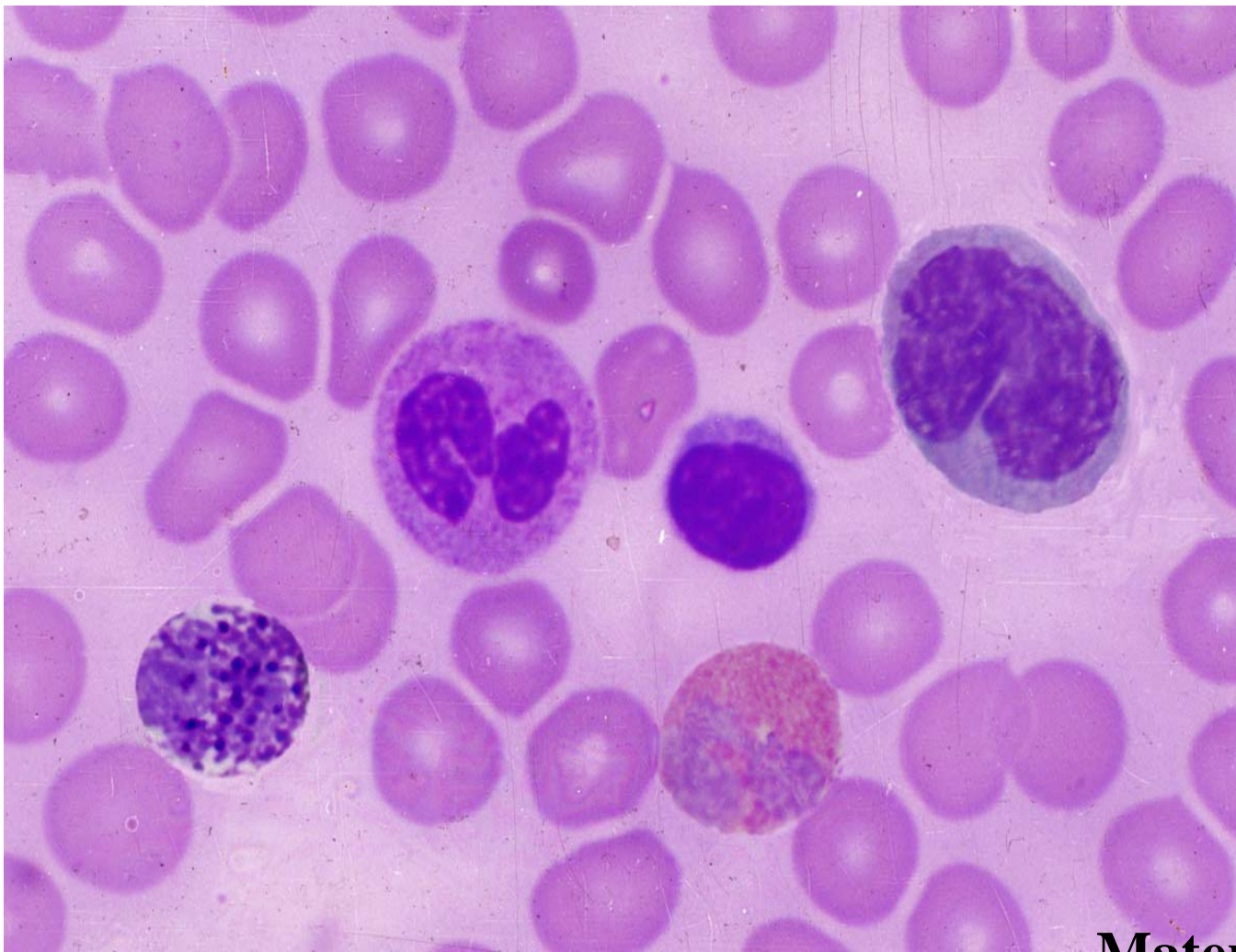
Reticulocyte



Myeloblast and metamyelocyte



Megakaryocyte



Blood cell

Material:

Staining:

Amplification:

Date:

Summary

- **the functions and structures of blood cells**